



www.figo.org

Contents lists available at ScienceDirect

## International Journal of Gynecology and Obstetrics

journal homepage: www.elsevier.com/locate/ijgo



## FIGO GUIDELINES

FIGO consensus guidelines on intrapartum fetal monitoring:  
Intermittent auscultation☆☆Debrah Lewis<sup>a</sup>, Soo Downe<sup>b</sup>; for the FIGO Intrapartum Fetal Monitoring Expert Consensus Panel<sup>1</sup><sup>a</sup> Mamatoto Resource and Birth Centre, Port of Spain, Trinidad<sup>b</sup> University of Central Lancashire, Preston, UK

## 1. Introduction

Intermittent auscultation is the technique used to listen to the fetal heart rate (FHR) for short periods of time without a display of the resulting pattern. Whether it is used for intrapartum fetal monitoring in low-risk women or for all cases in settings where there are no available alternatives, all healthcare professionals attending labor and delivery need to be skilled at performing intermittent auscultation, interpreting its findings, and taking appropriate action. The main aim of this chapter is to describe the tools and techniques for intermittent auscultation in labor.

## 2. Historical background

Hippocrates is said to have described the technique of listening to the internal activity of the body by placing the ear on the skin proximal to the organ under examination. However, the perception of fetal heart sounds using this method was not reported until the 1600s [1]. Little attention appears to have been given to fetal heart auscultation until 1818, when it was discussed by both Mayor and de Kergaradec [2] to determine whether the fetus was alive or dead. Interest then accelerated, and in 1833 Kennedy published a book on the subject of obstetric auscultation [3].

☆ Developed by the FIGO Safe Motherhood and Newborn Health Committee; coordinated by Diogo Ayres-de-Campos.

★ The views expressed in this document reflect the opinion of the individuals and not necessarily the institutions that they represent.

<sup>1</sup> Consensus panel: Daniel Surbek (Switzerland\*), Gabriela Caracostea (Romania\*), Yves Jacquemyn (Belgium\*), Susana Santo (Portugal\*), Lennart Nordström (Sweden\*), Tulia Todros (Italy\*), Branka Yli (Norway\*), George Farmakidis (Greece\*), Sandor Valent (Hungary\*), Bruno Carbone (France\*), Kati Ojala (Finland\*), José Luis Bartha (Spain\*), Joscha Reinhard (Germany\*), Anneke Kwee (Netherlands\*), Romano Byaruhanga (Uganda\*), Ehigba Enabudoso (Nigeria\*), Fadi Mirza (Lebanon\*), Tak Yeung Leung (Hong Kong\*), Ramon Reyes (Philippines\*), Park In Yang (South Korea\*), Henry Murray (Australia and New Zealand\*), Yuen Tannirandorn (Thailand\*), Krishna Kumar (Malaysia\*), Taghreed Alhaidary (Iraq\*), Tomoaki Ikeda (Japan\*), Ferdousi Begum (Bangladesh\*), Jorge Carvajal (Chile\*), José Teppa (Venezuela\*), Renato Sá (Brasil\*), Lawrence Devoe (USA\*\*), Gerard Visser (Netherlands\*\*), Richard Paul (USA\*\*), Barry Schifrin (USA\*\*), Julian Parer (USA\*\*), Philip Steer (UK\*\*), Vincenzo Berghella (USA\*\*), Isis Amer-Wahlin (Sweden\*\*), Susanna Timonen (Finland\*\*), Austin Ugwumadu (UK\*\*), João Bernardes (Portugal\*\*), Justo Alonso (Uruguay\*\*), Sabaratnam Arulkumaran (UK\*\*), Catherine Y. Spong (USA\*\*), Edwin Chandrharan (UK\*\*), Diogo Ayres-de-Campos (Portugal\*\*).

\*Nominated by FIGO associated national society; \*\* Invited by FIGO based on literature search.

The first recorded use of an amplification device for auscultation of the adult heart rate is attributed to Laënnec in 1816, who overcame the embarrassment of placing the ear on a young woman's chest to hear her heart beat by rolling sheets of paper into a tube and listening through this device [2]. This tool was soon replicated in wood, and gained wide usage for fetal heart auscultation. The most common instrument currently used for this purpose is the Pinard stethoscope (Figs. 1 and 2), but in some countries, notably the USA, the DeLee stethoscope is used as an alternative (Fig. 3). In both cases, the technology has not changed much from the original design, in which a belled tube creates an amplification chamber for sound waves that are transmitted from the fetal heart to the examiner's ear.

More recently, handheld electronic devices that rely on the Doppler effect have been used for intermittent auscultation (Fig. 4), a technology similar to the external FHR monitoring of cardiotocography (CTG). However, as described in the chapter on CTG [4], these devices do not transmit the actual sound produced by the fetal heart, but rather a representation of this, based on ultrasound-detected movements of fetal cardiac structures, that are then subject to signal modification and auto-correlation. Table 1 compares the advantages and disadvantages of the three instruments currently used for intermittent auscultation.

## 3. Objectives and indications

As for other approaches to fetal monitoring, the main aim of intermittent auscultation is the timely identification of fetuses with hypoxia/acidosis to enable appropriate action before the occurrence of injury. It also allows the confirmation of normal FHR characteristics, so that unnecessary intervention will be avoided. Systematic reviews of randomized controlled trials carried out in the 1970s, 1980s, and early 1990s, comparing intermittent auscultation with continuous CTG for intrapartum monitoring in both low- and high-risk women, have shown that CTG is associated with a lower risk of neonatal seizures, but with higher cesarean and instrumental vaginal delivery rates [5]. The limitations of this evidence are analyzed in the chapter on CTG [4]. There is currently no conclusive evidence for the benefits of continuous CTG versus intermittent auscultation monitoring in labor. There are also no trials comparing intermittent auscultation with no FHR auscultation during labor.

Based on expert opinion, intermittent auscultation should be recommended in all labors in settings where there is no access to CTG monitors or to the resources necessary for using them. When the resources

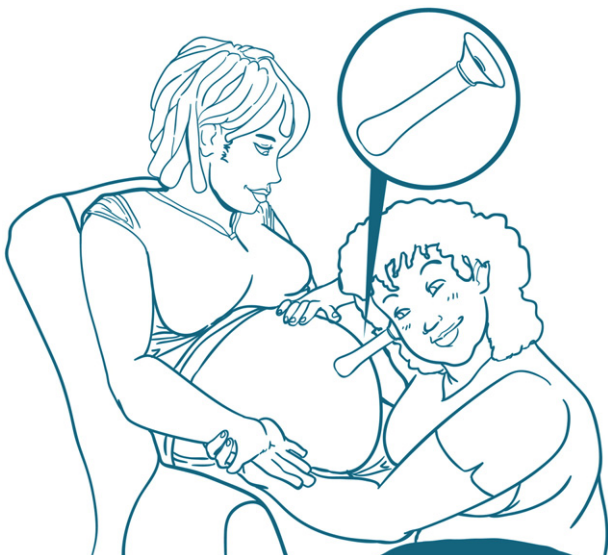


**Fig. 1.** A Pinard stethoscope.

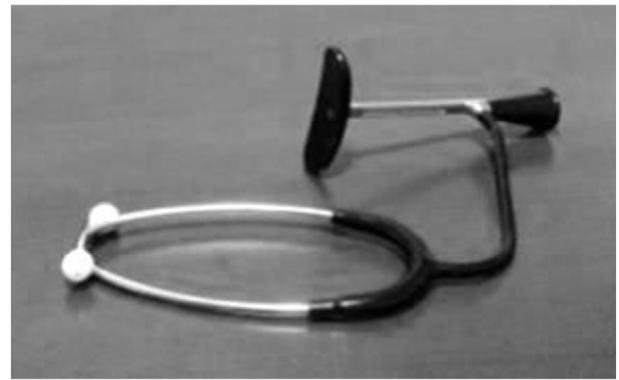
for CTG monitoring are available, intermittent auscultation may be used for routine intrapartum monitoring in low-risk cases (Table 2). However, approximately half of the panel members believe that continuous CTG should be the option during the second stage of labor, although there is no direct scientific evidence to support this.

#### 4. Advantages of intermittent auscultation

Performing regular intermittent auscultation ensures frequent contact between healthcare professionals and the laboring woman, offering the opportunity for social and clinical support. It facilitates the



**Fig. 2.** Pinard stethoscope in use.



**Fig. 3.** A DeLee stethoscope.

assessment of other physical parameters such as maternal skin tone, temperature, breathing patterns, direct palpation of fetal movements, and maternal contractions.

Intermittent auscultation permits the fetal heart to be monitored in various positions and locations and favors the mobility of laboring women, which has been shown to benefit the progress of labor [7]. Another benefit of intermittent auscultation is the easier availability and sustainability of the technology, which allows it to be undertaken in even the lowest resource settings.

#### 5. Disadvantages of intermittent auscultation

It takes time to develop clinical expertise with intermittent auscultation when performed with a fetal stethoscope [8,9]. Initially it may not be easy to recognize the fetal heart sounds, and later there is a slow learning curve for the identification of accelerations and decelerations. Even for the most experienced healthcare professionals, it is impossible to recognize subtle features of the FHR, such as variability. Using fetal stethoscopes, awkward positions sometimes need to be adopted for effective auscultation and therefore healthcare professionals should ensure good ergonomic position for themselves and the laboring woman when using intermittent auscultation. Also with these instruments, there is no independent record of the FHR and usually no confirmation of the findings by other healthcare professionals, or by those in the room. This may cause uncertainty in case reviews and medico-legal cases.



**Fig. 4.** Handheld Doppler device.

**Table 1**  
Advantages and disadvantages of the instruments used for intermittent auscultation.

	Advantages	Disadvantages
Pinard stethoscope	Inexpensive Readily available in most countries No consumables needed	May be difficult to use in certain maternal positions
DeLee stethoscope	Inexpensive Readily available in some countries No consumables needed	May be difficult to use in certain maternal positions
Handheld Doppler	More comfortable for the woman FHR audible to all present in the room Can be used in various maternal positions and locations (e.g. in water) May calculate and display FHR values	More costly to purchase and maintain (requires batteries) Probe is very sensitive to mechanical damage May display maternal heart rate

**Table 2**  
Conditions required for considering and maintaining intermittent auscultation in settings where cardiotocography is available.

Antepartum factors	Intrapartum factors
No serious previous maternal health conditions	Normal frequency of contractions
No maternal diabetes or pre-eclampsia	No labor induction or augmentation
No antenatal vaginal hemorrhage	No epidural analgesia
Normal fetal growth, amniotic fluid, and Doppler	No abnormal vaginal hemorrhage
Normal antenatal cardiotocography readings	No fresh or thick meconium
No previous uterine scar	No maternal temperature >38°C
Normal fetal movements	Active first stage lasting <12 hours
No rupture of membranes lasting >24 hours	Second stage lasting <1 hour
Singleton, term, cephalic presentation	Clearly audible fetal heart rate sounds in normal range

Source: Maude et al. [6].

Many of these disadvantages are overcome by the use of a handheld Doppler. When this device includes a display showing the FHR, even low variability may be suspected. On the other hand, as occurs with external FHR monitoring in CTG, the device can inadvertently pick up the maternal heart rate.

Whichever method of intermittent auscultation is used, it may be difficult to guarantee the continued availability of appropriately trained staff to attend laboring women in busy labor units.

## 6. Technique for performing intermittent auscultation

Before intermittent auscultation is initiated, a clear explanation of the technique and its purpose should be provided to the laboring

**Table 3**  
Practice recommendations for intermittent auscultation, uterine contraction, and maternal heart rate monitoring during labor.

Features to evaluate		What to register
FHR	Duration: for at least 60 seconds; for 3 contractions if the FHR is not always in the normal range (110–160 bpm). Timing: during and at least 30 seconds after a contraction. Interval: Every 15 minutes in the active phase of the first stage of labor. Every five minutes in the second stage of labor.	Baseline (as a single counted number in bpm), presence or absence of accelerations and decelerations.
Uterine contractions	Before and during FHR auscultation, in order to detect at least two contractions.	Frequency in 10 minutes.
Fetal movements	At the same time as evaluation of uterine contractions.	Presence or absence.
Maternal heart rate	At the time of FHR auscultation.	Single counted number in bpm.

Abbreviation: FHR, fetal heart rate; bpm, beats per minute.

woman, and her consent obtained. This is followed by an assessment of the fetal position on abdominal palpation, and placement of the stethoscope or handheld Doppler over the fetal back as this is where the heart rate will usually be heard most clearly. Searching for sounds produced by the fetal heart (usually compared to a “galloping horse”) rather than those created by fetal vessels (“whoosh” sounds) allows for a clearer distinction from maternal heart rate. Simultaneous evaluation of the maternal pulse provides additional reassurance that the FHR is being monitored. Just before and during intermittent auscultation, a hand is placed on the uterine fundus to determine the timing of uterine contractions and to detect fetal movements. If the fetal heart cannot be identified unambiguously, ultrasound should be used when available to determine the FHR and to establish the optimal location for intermittent auscultation.

There are no studies comparing the benefit of different auscultation intervals. In large randomized trials comparing CTG with intermittent auscultation, the latter was usually performed every 15 minutes in the first stage and every five minutes or after every other contraction in the second stage [5]. While it is recognized that recommendations for the scheduling of intermittent auscultation are based only on expert opinion, standardization of procedures is important for planning of health care and for medical – legal purposes. The recommendations for performing intermittent auscultation are considered in Table 3.

All features listed in Table 3 should be recorded in dedicated labor charts to provide an ongoing account of their evolution, and to share information between caregivers who are or may become involved in the process.

## 7. Abnormal findings and their management

### 7.1. In settings where continuous CTG is available

Abnormal findings on intermittent auscultation are listed in Table 4. If there is doubt as to the characterization of FHR findings, auscultation should be prolonged in order to cover at least three contractions.

An FHR value under 110 bpm lasting more than three minutes, when the rate has previously been normal, is strongly suggestive of a prolonged deceleration or of fetal bradycardia, and constitutes an indication for immediate continuous CTG. An FHR value exceeding 160 bpm during three contractions is strongly suggestive of fetal tachycardia, and constitutes an indication for continuous CTG.

Sometimes, decelerations occur because of the maternal supine position and resulting aortocaval compression. Changing the maternal position may quickly revert the situation. However, if a rapid normalization does not ensue, or if repetitive or prolonged decelerations are detected, continuous CTG should be started.

Most accelerations coincide with fetal movements detected by the mother and/or the healthcare professional, and are a sign of fetal well-being. However, accelerations occurring just after a contraction do not usually translate to fetal movements and should motivate auscultation over at least three contractions in order to rule out the occurrence of decelerations.

**Table 4**  
Abnormal findings on intermittent auscultation.

	Abnormal finding
Baseline	Below 110 bpm or above 160 bpm
Decelerations	Presence of repetitive or prolonged (>3 minutes) decelerations
Contractions	More than five contractions in a 10-minute period

Abbreviation: bpm, beats per minute.

An interval between two contractions of less than two minutes should lead to evaluation of uterine contractions over 10 minutes. More than five contractions detected during this period is considered tachysystole (see CTG chapter [4]). This constitutes an indication for continuous CTG, at least until the situation is reversed.

If assessment of the parameters described in Table 3 and the general behavior of the mother indicate the continuous well-being of both mother and baby, intermittent auscultation may continue to be the technique of choice for labor.

### 7.2. In settings where continuous CTG is not available

If an FHR value under 110 bpm lasting more than five minutes is detected—in the absence of maternal hypothermia, known fetal heart block, or beta-blocker therapy—consideration should be given to immediate delivery by cesarean or instrumental vaginal delivery, according to obstetric conditions and local resources.

An FHR value exceeding 160 bpm during at least three contractions is suggestive of fetal tachycardia, and should motivate an evaluation of maternal temperature and signs of intrauterine infection. Beta-agonist drugs (salbutamol, terbutaline, ritodrine, fenoterol) and parasympathetic blockers (atropine, scopolamine) are other possible causes. With isolated fetal tachycardia, increased frequency of intermittent auscultation and treatment of pyrexia and/or infection need to be considered.

Repetitive decelerations are frequent during the second stage of labor and may occur as a result of aortocaval, umbilical cord, or fetal head compression. Changing the maternal position may revert the first two causes. However, if decelerations start more than 20 seconds after the onset of a contraction and take more than 30 seconds to recover to baseline values (late decelerations), or when decelerations last more than three minutes (prolonged decelerations), this is strongly suggestive of fetal hypoxia/acidosis. If an accompanying tachysystole is detected, consideration should be given to acute tocolysis with beta-

adrenergic agonists (salbutamol, terbutaline, ritodrine), atosiban, or nitroglycerine (see physiology chapter [10]), followed by continued auscultation to document the normalization of the pattern. Sudden maternal hypotension rarely happens during labor in the absence of conduction analgesia, but should it occur in association with a fetal deceleration, increased intravenous fluid administration turning the mother to her side and administering intravenous ephedrine will usually revert the situation. When late and/or prolonged decelerations are documented during the second stage of labor, the mother should be asked to stop pushing until this pattern disappears. If there is no rapid reversal of late and/or prolonged decelerations, consideration should be given to immediate delivery, by cesarean or instrumental vaginal delivery, according to obstetric conditions and local resources.

### Conflict of interest

The authors have no conflicts of interest.

### References

- [1] O'Dowd MJ, Philipp EE. The History of Obstetrics and Gynaecology. New York: Parthenon Publishing Group; 1994.
- [2] Freeman RK, Garite TJ, Nageotte MP, Miller LA. History of fetal monitoring. In: Fetal Heart Rate Monitoring. Philadelphia: Lippincott Williams and Wilkins; 2012.
- [3] Kennedy E. Observations on obstetric auscultation. Dublin: Hodges and Smith; 1833. <https://archive.org/details/observationsonob1833kenn>. Accessed November 17, 2014.
- [4] Ayres-de-Campos D, Spong CY, Chandraran E. FIGO Intrapartum Fetal Monitoring Expert Consensus Panel. FIGO consensus guidelines on intrapartum fetal monitoring: Cardiotocography. Int J Gynecol Obstet 2015;131(1):13–24 (in this issue).
- [5] Alfirevic Z, Devane D, Gyte GM. Continuous cardiotocography (CTG) as a form of electronic fetal monitoring (EFM) for fetal assessment during labour. Cochrane Database Syst Rev 2013;5:CD006066.
- [6] Maude RM, Skinner JP, Foureur MJ. Intelligent Structured Intermittent Auscultation (ISIA): evaluation of a decision-making framework for fetal heart monitoring of low-risk women. BMC Pregnancy Childbirth 2014;14:184.
- [7] Lawrence A, Lewis L, Hofmeyr GJ, Styles C. Maternal positions and mobility during first stage labour. Cochrane Database Syst Rev 2013;8:CD003934.
- [8] Miller FC, Pearse KE, Paul RH. Fetal heart rate pattern recognition by the method of auscultation. Obstet Gynecol 1984;64(3):332–6.
- [9] Schiffrin BS, Amsel J, Burdorf G. The accuracy of auscultatory detection of fetal cardiac decelerations: a computer simulation. Am J Obstet Gynecol 1992;166(2):566–76.
- [10] Ayres-de-Campos D, Arulkumaran S. FIGO Intrapartum Fetal Monitoring Expert Consensus Panel. FIGO consensus guidelines on intrapartum fetal monitoring: Physiology of fetal oxygenation and the main goals of intrapartum fetal monitoring. Int J Gynecol Obstet 2015;131(1):5–8 (in this issue).